

Images in clinical medicine



Antero ventricular malformation: an uncommon clinical image

 Chanchala Mujbaile, Vaishnavi Yadav

Corresponding author: Chanchala Mujbaile, Department of Oncology Physiotherapy, Ravi Nair Physiotherapy College, Datta Meghe Institute of Higher Education and Research, Sawangi (Meghe), Wardha, India. chanchalasmujbaile@gmail.com

Received: 15 Jan 2026 - **Accepted:** 07 Feb 2026 - **Published:** 14 Apr 2026

Keywords: Arteriovenous malformation, serpiginous vessels, retroauricular region

Funding: This research received no specific grant from any funding agency in the public, commercial, or not-for-profit sectors.

Copyright: Chanchala Mujbaile et al. PAMJ Clinical Medicine (ISSN: 2707-2797). This is an Open Access article distributed under the terms of the Creative Commons Attribution International 4.0 License (<https://creativecommons.org/licenses/by/4.0/>), which permits unrestricted use, distribution, and reproduction in any medium, provided the original work is properly cited.

Cite this article: Chanchala Mujbaile et al. Antero ventricular malformation: an uncommon clinical image. PAMJ Clinical Medicine. 2026;20(19). 10.11604/pamj-cm.2026.20.19.51128

Available online at: <https://www.clinical-medicine.panafrican-med-journal.com//content/article/20/19/full>

Antero ventricular malformation: an uncommon clinical image

Chanchala Mujbaile^{1,&}, Vaishnavi Yadav²

¹Department of Oncology Physiotherapy, Ravi Nair Physiotherapy College, Datta Meghe Institute of Higher Education and Research, Sawangi (Meghe), Wardha, India, ²Department of Cardiovascular and Respiratory Physiotherapy, Ravi Nair Physiotherapy, College Datta Meghe Institute of Higher Education and Research Sawangi (Meghe) Wardha, India

[&]Corresponding author

Chanchala Mujbaile, Department of Oncology Physiotherapy, Ravi Nair Physiotherapy College, Datta Meghe Institute of Higher Education and Research, Sawangi (Meghe), Wardha, India

Image in medicine

A 49-year-old female patient presented with the complaint of swelling over the left lower jaw that initially occurred 30 years ago. She had an intra-articular mass in her left parotid and was advised to undergo surgery. An arteriovenous malformation is a rare high-flow vascular abnormality characterised by direct connections between arteries and veins that lack an intervening capillary bed. The condition is gradually progressive, with pulsatile masses, and poses severe diagnostic difficulties due to its complex vascular structure. Clinically, swelling in the area was soft, pulsatile, and partially compressible. MRI Scan revealed that there is a large altered signal intensity lesion showing a tangle of serpiginous vessels on post contrast

study noted in the intramuscular plane in the left parotid region of approximate size 5.2 x 9.2 x 7.4 cm seen extending superiorly up to the external auditory channel, inferiorly in upper neck region and laterally causing outward bulge on skin, medially reaching upto Buccal mucosa. The lesion has arterial feeders from branches of the left external carotid artery and early venous drainage into tributaries of the left EJV; a few vessels also drain into IJV. The Left subclavian vein is dilated and tortuous. Management and Therapeutic intervention include surgical removal of part; further short-term management will be planned based on the patient's condition and standard surgical protocol. The receptor profile will guide medium-term management, including the surgical site dressing. Long-term management will be routine follow-ups.

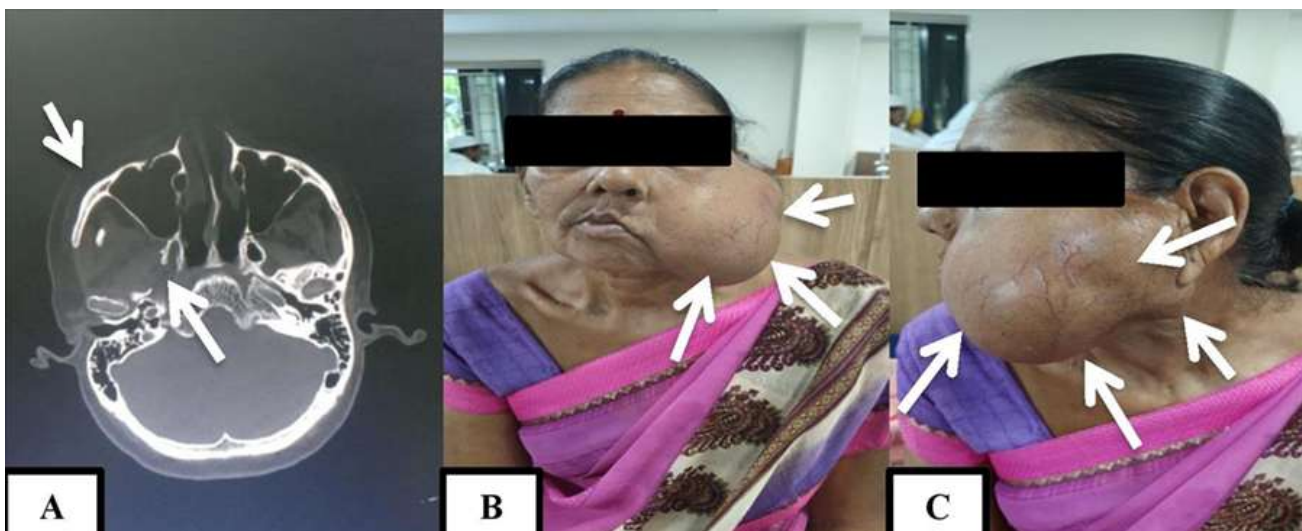


Figure 1: A) vascular lesion in the left parotid region, extending to retroauricular area; B) lesion size was 5.2 X 9.2 X 7.4 cm and comprised of a mass of serpiginous vessels with significant post-contrast enhancement; C) arterial feeders developed off the left external carotid artery having an early venous drain into external and internal jugular veins