

Images in clinical medicine



Hyperpion: a diagnosis to keep in mind

Aymane Ridallah, Alae El bouaychi

Corresponding author: Aymane Ridallah, University Mohammed V Souissi, Ophtalmologie A, l'Hôpital des Spécialités, CHU Rabat, Maroc. aridallah@gmail.com

Received: 04 Jun 2020 - **Accepted:** 07 Jun 2020 - **Published:** 08 Jun 2020

Keywords: Hyperpion, silicone oil, inverse hypopion

Copyright: Aymane Ridallah et al. PAMJ Clinical Medicine (ISSN: 2707-2797). This is an Open Access article distributed under the terms of the Creative Commons Attribution International 4.0 License (<https://creativecommons.org/licenses/by/4.0/>), which permits unrestricted use, distribution, and reproduction in any medium, provided the original work is properly cited.

Cite this article: Aymane Ridallah et al. Hyperpion: a diagnosis to keep in mind. PAMJ Clinical Medicine. 2020;3(44). 10.11604/pamj-cm.2020.3.44.24035

Available online at: <https://www.clinical-medicine.panafrican-med-journal.com//content/article/3/44/full>

Hyperpion: a diagnosis to keep in mind

Aymane Ridallah^{1,&}, Alae El bouaychi¹

¹University Mohammed V Souissi, Ophtalmologie A, l'Hôpital des Spécialités, CHU Rabat, Maroc

&Corresponding author

Aymane Ridallah, University Mohammed V Souissi, Ophtalmologie A, l'Hôpital des Spécialités, CHU Rabat, Maroc

Image in medicine

We report the case of a 55 old patient, with a high myopic right eye, who presented 6 months ago, a retinal detachment, having benefited from endo-ocular surgery with silicone oil tampon. The patient has been showing a whitish appearance in the eye since 3 months, gradually increasing in size, which motivated him to consult in our eye clinic. The ocular tonus is at 22 mmhg. Ophthalmological examination evidenced the presence of a “frothy white formation” at the top anterior chamber. The hyperpion or commonly called “inverse hypopion”, is due to an emulsification of silicone oil, when it passes into the anterior chamber and comes into contact with aqueous humor, which acquires a whitish appearance, and migrates to the top of the anterior chamber. In this situation, we removed the silicone oil with active drainage and air-fluid, associated with a washing of the anterior chamber.

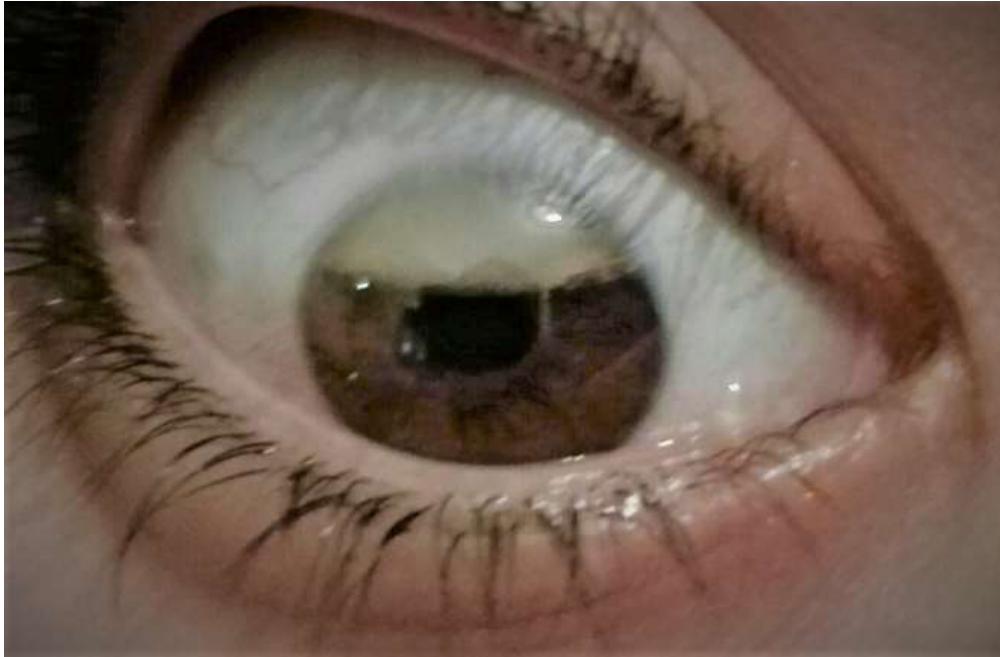


Figure 1: emulsified silicone oil in the anterior chamber